



Short communication

Liposarcoma at the site of an implanted microchip in a dog

Marta Vascellari ^a, Franco Mutinelli ^{a,*}, Romina Cossetini ^b, Emanuela Altinier ^b^a Istituto Zooprofilattico Sperimentale delle Venezie, Histopathology Department, Viale dell'Università 10, 35020 Legnaro (PD), Italy^b Veterinary Surgeon, Via Tulipifero 11, 33080 Porcia (PN), Italy

Accepted 25 June 2003

Keywords: Dog; Liposarcoma; Microchip; Foreign body reaction; Identification

An 11-year-old male, mixed breed dog was examined by the referring veterinarian for a subcutaneous mass, located in the lateral region of the neck, craniodorsally to the top of the left shoulder blade. The dog was regularly vaccinated and identified by a microchip (Indexel, Merial), which had been implanted in April 2000.

The owner reported that he had first noticed the development of a small nodule at the site of the microchip implantation, in November 2001. At time of referral the mass was 10 × 6 cm, firm and painless. Using an image intensifier, the microchip was located in the subcutaneous fascia at the base of the mass (Fig. 1). This mass appeared to have developed in the subcutis, around the microchip itself, causing bulging of the skin contour. A complete physical examination excluded any further changes. Results of a complete pre-operative blood count and serum biochemistry analysis were within normal ranges. Thoracic radiographs, lateral and dorsoventral views, taken to exclude pulmonary metastasis, were normal. Following the veterinarian's advice, the owner decided to have the mass excised. On April 2003, surgery was performed under general anaesthesia. An elliptical excision with wide margins was made around the mass, which was well delimited and easily separated from the surrounding tissues. After surgery, the dog was discharged with routine antibiotic treatment for two weeks. Despite some post-operative exudation, treated by drainage, the surgical wound was completely healed within one month.

Macroscopically, the mass appeared dark reddish due to haemorrhages and abundant vascularisation; it had a bumpy surface and was friable on sectioning. The intact

microchip was found completely embedded within the mass.

Histological examination revealed a poorly defined neoplastic proliferation of readily recognisable adipose cells and poorly differentiated cells, with pleomorphic hyperchromatic nuclei and abundant cytoplasm containing lipid droplets (Fig. 2). Few mitotic figures were detected. An interstitial stroma was present consisting of fibrous septa, without capsule formation. Some multinucleated giant cells were present. The surgical margins appeared to be complete. On the basis of the histopathological findings a diagnosis of low-grade liposarcoma was made.

Microchipping is a safe, painless, indelible identification technique for dogs and cats, widely used after the advent of the Pet Travel Scheme (Fooks et al., 2002). The microchip consists of a sealed glass capsule containing a chip and a coil. The Indexel microchip is also equipped with an anti-migrational capsule, located in the anterior part of the microchip, to prevent migration after implantation. The capsule is made from bioglass, the main components of which are silicon, sodium, calcium, potassium, magnesium, iron and aluminium, and has been classified in the silicon sodium group (Jansen et al., 1999). One of the properties of such bioglasses is their insolubility, and they tend to become encapsulated with fibrous tissue when implanted subcutaneously (Lammers et al., 1995; Geisel et al., 1998). The apparent biocompatibility of the bioglass with animal tissues formed the basis for its final application on a wide scale.

Currently, thousands of microchips are implanted into dogs, cats and horses each year. However, despite clear advantages over other identification techniques, some adverse reactions to microchips, including migration,

* Corresponding author. Tel.: +39-49-8084261; fax: +39-49-8084258.
E-mail address: fmutinelli@izsvenezie.it (F. Mutinelli).

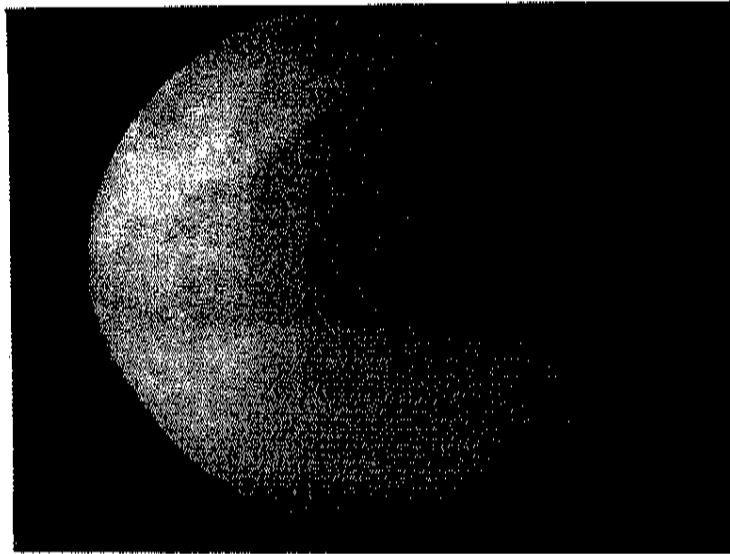


Fig. 1. The microchip was detected in the subcutaneous fascia, at the basis of the neoplastic mass, by image intensifier.

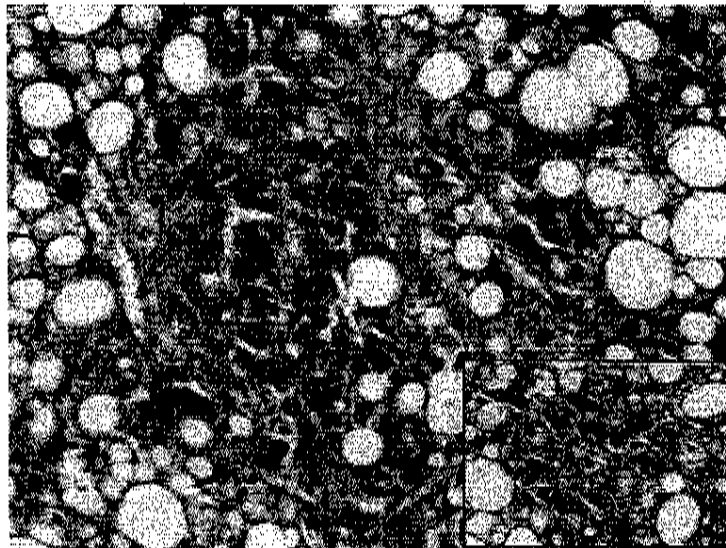


Fig. 2. Histological appearance of the mass. Neoplastic proliferation of readily recognisable adipose cells and poorly differentiated cells, with abundant cytoplasm containing lipid droplets were evident (H&E, 20 \times). Multinucleated giant cells were detected within the tumour (Inset, 40 \times).

infection, failure to work or loss from the body have been reported (Jansen et al., 1999; Swift, 2000, 2002). In September 1997, the British Small Animal Veterinary Association (BSAVA), in conjunction with the Federation of European Companion Animal Veterinary Associations (FECAVA) launched a scheme to record information on adverse reactions to microchips (Swift, 1997). Between September 1997 and December 2001 a total of 147 reports were received from UK and other European countries. The most frequent adverse reactions were migration (89 reports), followed by complete loss from the body (35 reports) and functional failure (15 reports).

Infection and swelling were less commonly noted, with only six and two reports, respectively (Swift, 2000, 2002).

To the authors' knowledge, tumours arising at the sites of microchip implantation have never been reported. In contrast, some cases of soft tissue tumours surrounding a microchip have been described in laboratory mice and rats (Tillmann et al., 1997; Blanchard et al., 1999; Elcock et al., 2001). All the tumours described in these papers were mesenchymal in origin and contained embedded microchips. The mechanism of carcinogenicity was ascribed to a foreign body induced tumourigenesis (Elcock et al., 2001).

In dogs, liposarcoma is an uncommon neoplasm and no sex or breed predilection is known. Moreover, no causative agent has been associated with liposarcoma in dogs. Liposarcomas tend to be aggressive, locally invasive and may metastasise to lung, liver and bone (MacEwen et al., 2001). A case of liposarcoma associated with a glass foreign body has been reported in a dog (McCarthy et al., 1996) but in that report, the neoplasia developed 10 years after the accidental glass implantation. The histopathological features were comparable with those described in the present case, including mild cellular pleomorphism and the presence of some giant cells. Foreign body induced sarcomas have been described in humans, although with a low prevalence, including osteosarcomas, rhabdomyosarcomas, haemangiosarcomas and liposarcomas.

Development of foreign body sarcomas depends on the size and physical and chemical properties of the foreign material. The surface texture of the foreign body also appears to be important. In fact, smooth surface bodies seem to be more tumourigenic than those with rough surfaces (Brand, 1975). Treatment for liposarcoma should include an early surgical excision with wide margins, while radiation and chemotherapy seem to be unresponsive (MacEwen et al., 2001). Prognosis depends on the extent of the local disease, and long-term outcome is related to the size and site of the lesion, histological grade and whether the neoplasm is attached to underlying tissues (MacEwen et al., 2001). In the present case, the mass was excised a long time after it had first been seen, and by the time of surgery it had reached a large size. However, neither regional lymphadenopathy nor pulmonary metastasis were noted. Furthermore, the mass was well circumscribed and the surrounding tissues were not infiltrated. Histologically, the surgical margins were complete and the degree of cellular pleomorphism was consistent with a low grade of malignancy. These factors led to a favourable prognosis. Three months after surgery the dog showed no signs of recurrence.

Despite the huge number of microchips that are implanted annually in pets, the number of adverse reactions reported is limited, with migration, loss from the body and failure to work being the most common. Inflammatory reactions such as swelling and abscessation are unusual. Tumours have not been associated previously with microchip implantation in pets. Veterinary

surgeons are therefore encouraged to check the microchips that have been implanted in pets at least annually, such as when they come in for vaccinations, and report any adverse reaction.

References

- Blanchard, K.T., Barthel, C., French, J.E., Holden, H.E., Moretz, R., Pack, F.D., Tennant, R.W., Stoll, R.E., 1999. Transponder-induced sarcoma in the heterozygous p53+/- mouse. *Toxicological Pathology* 27, 519-527.
- Brand, K.G., 1975. Foreign body sarcomas. In: Becker, F.F. (Ed.), *Cancer, a Comprehensive Treatise*. Vol. I: Chemical and Physical Carcinogenesis. Plenum Press, New York, pp. 485-508.
- Elcock, L.E., Stuart, B.P., Wahle, B.S., Hoss, H.E., Crabb, K., Millard, D.M., Mueller, R.E., Hasting, T.F., Lake, S.G., 2001. Tumors in long-term rat studies associated with microchip animal identification devices. *Experimental Toxicological Pathology* 52, 483-491.
- Fooks, A.R., McElhinney, L.M., Brookes, S.M., Johnson, N., Keene, V., Parsons, G., Soldan, A., 2002. Rabies antibody testing and the UK pet travel scheme. *The Veterinary Record* 150, 428-430.
- Geisel, O., Klindtworth, M., Wendl, G., Schön, H., Hermanns, W., 1998. Transponder bei Rindern: Histologische Befunde zehn und zwölf Monate nach subkutaner implantation. *Tierärztliche Umschau* 53, 192-200.
- Jansen, J.A., van der Waerden, J.P.C.M., Gwalter, R.H., van Rooy, S.A.B., 1999. Biological and migrational characteristics of transponders implanted into beagle dogs. *Veterinary Record* 145, 329-333.
- Lammers, G.H., Langeveld, N.G., Lambooi, E., Gruys, E., 1995. Effects of injecting electronic transponders into the auricle of pigs. *Veterinary Record* 136, 606-609.
- Withrow, S.J., Powers, B.E., Macy, D., Withrow, S.J., 2001. Soft tissue sarcomas. In: Withrow, S.J., MacEwen, E.G. (Eds.), *Small Animal Clinical Oncology*. W.B. Saunders Company, Philadelphia, pp. 283-304.
- McCarthy, P.E., Hedlund, C.S., Veazy, R.S., Prescott-Mathews, J., Cho, D.-Y., 1996. Liposarcoma associated with a glass foreign body in a dog. *Journal of the American Veterinary Medical Association* 209, 612-614.
- Swift, S., 1997. Microchip adverse reactions reporting scheme. *Journal of Small Animal Practice* 38, 370.
- Swift, S., 2000. Microchip adverse reactions. *Journal of Small Animal Practice* 41, 232.
- Swift, S., 2002. Keeping track of microchip adverse reactions. *Journal of Small Animal Practice* 43, 570.
- Tillmann, T., Kamino, K., Dusenbrock, C., Ernst, H., Kohler, M., Morawietz, G., Campo, E., Cardesa, A., Tomatis, L., Mohr, U., 1997. Subcutaneous soft tissue tumours at the site of implanted microchips in mice. *Experimental Toxicological Pathology* 49, 197-200.