

Tissue Reaction to an Implantable Identification Device in Mice*

GHANTA N. RAO AND JENNIFER EDMONDSON

*National Toxicology Program, Division of Toxicology Research and Testing,
National Institute of Environmental Health Sciences,
Research Triangle Park, North Carolina 27709*

ABSTRACT

Long-term toxicity and carcinogenicity studies require positive identification of animals. Due to the unreliability of traditional methods, it was necessary to investigate more dependable identification methods that can be read directly or by electronic means. A two-year study to determine the stability of and tissue reaction to a microchip glass-sealed device implanted in subcutaneous tissue of mice was conducted. Seventy B6C3F1 mice of each sex were anesthetized and implanted with the microchip. The devices were read by an electronic detector and palpated at periodic intervals. Ten mice of each sex were necropsied at 3 months and at 15 months with the remaining animals necropsied at 24 months. Of the 140 devices implanted, 3 were lost and 4 failed during the 24-month study. Devices were palpable and appeared to be fixed at one location with no obvious swelling due to inflammation or palpable masses around the implants for 24 months. At the 3, 15, and 24 month necropsies, implants were encapsulated by connective tissue. Light microscopic evaluation indicated that the capsule around the implants was thin and composed of fibrocytes and mature collagen fibers, with minimal to mild inflammation and occasional granulomatous reaction. Neoplastic changes were not observed in the tissue around the glass-sealed devices with polypropylene cap for up to 24 months.

Keywords. Microchip implant; glass-sealed implant; polypropylene implant; connective tissue capsule; granulomatous reaction; foreign body tissue reaction

INTRODUCTION

Positive identification of small rodents such as mice, rats, and hamsters is essential in chronic toxicity and carcinogenicity studies. Current methods of identification such as ear notches and ear tags may be lost due to fighting or due to the ears being caught in feeders and other parts of the cage. Furthermore, metallic ear tags may cause chronic infections and inflammation, proliferative changes and neoplastic lesions at the site of the tag (8). Identification by toe clip may be considered a painful procedure (4) and may not be acceptable. The small rodents used in toxicity studies may vary in color from albino to brown or black and tattoo methods may not be reliable in pigmented rodents.

A unique and permanent identification that can be read by unaided eye or by electronic means is desirable. The unique identification method must be a humane procedure and should be readable ir-

respective of the color of the skin and fur of the animal for up to 3 years duration. If it is an implantable identification device, it should be small enough to be implanted subcutaneously in a 15 g mouse without appreciable displacement of the surrounding tissue. Since glass, plastic, silicone and other solid inert materials may cause foreign body sarcoma (2), the implantable device should be made or sealed with biosafe materials eliciting minimal tissue reaction.

A microchip implantable device, sealed in glass and cylindrical in shape measuring 12 mm in length and 2 mm in diameter, is currently available (Bio Medic Data Systems, Inc.). This device can be implanted in the subcutaneous tissue of a 15–20 g mouse. The prevalence of subcutaneous tissue sarcomas was reported as high as 12% in the male B6C3F1 mice used in the National Cancer Institute (NCI) and National Toxicology Program (NTP) carcinogenesis studies (5). If the microchip implant does cause sarcoma in the subcutaneous tissue around the implant, it may complicate the interpretation of carcinogenesis studies. Therefore, the purpose of this study was to determine the tissue reaction, espe-

* Address correspondence to: Dr. Ghanta N. Rao, NIEHS/NTP, MD AO-01, P.O. Box 12233, Research Triangle Park, North Carolina 27709.

cially its potential to cause subcutaneous sarcoma, and the stability and reliability of a glass-sealed permanent identification device (Bio Medic Data Systems, Inc.) when implanted in the subcutaneous tissue of B6C3F1 mice for up to 2 years.

MATERIALS AND METHODS

Device

The implantable micro-identification device (IMI¹) is a battery-free, passive miniature transponder with its own 10-digit hexi-decimal laser encoded permanent and unalterable identification number (e.g., 7F7E365379, 7F7E2D355C, 7F7E1E7D4F, etc.). It is a glass-sealed 12 × 2 mm cylindrical device with a snug-fit biocompatible polypropylene cap covering a 5 mm length of the device. There are 2 holes in the polypropylene cap. A functional device with polypropylene cap is shown in Fig. 1A. The purpose of the polypropylene cap with holes is to elicit mild tissue reaction and immobilize the device at the site of implantation. The device is activated by a low power radiofrequency signal and transmits its unique identification number to a transponder reader.

Animals

The B6C3F1 (C57BL/6N × C3H/HeN MTV-) mice used for this study were the progeny of Charles River altered Schaedler microflora associated foundation colony breeding stocks derived from the National Institutes of Health (NIH) genetic colonies. The hybrid mice produced under barrier conditions in a NTP production colony² were received at the National Institute of Environmental Health Sciences (NIEHS) when they were 4 weeks of age. These mice were quarantined and acclimated for 2 weeks at which time they were determined to be pathogen free. Seventy mice of each sex were randomly selected for the study. Mice were housed individually in hanging drawer type solid bottom polycarbonate cages (23.5 × 15.2 × 16.5 cm) with heat treated hardwood bedding in stainless steel racks³ and fed NIH-07⁴ (6) pelleted diet. Animal use and care was in accordance with the United States Public Health Service policy on humane care and use of laboratory animals and the *Guide for the Care and Use of Laboratory Animals* (7). The study was conducted in AAALAC⁵ accredited facility of NIEHS with a pro-

ocol approved by the NIEHS Animal Care and Use Committee.

Treatment and Observations

After quarantine, the mice were anesthetized with methoxyflurane and a transponder (IMI) was implanted in the subcutaneous tissue of the dorsal abdominal and thoracic areas with a sterile 12 gauge thin wall stainless steel needle with a transponder prepackaged in the lumen of the needle⁶. The injection site was disinfected with 70% alcohol before implantation and was allowed to heal without sutures or wound clips. The mice were observed at least once daily for moribundity and mortality. The devices were scanned with a low power radiofrequency signal probe reader at weekly intervals and palpated at 4–5 week intervals for tissue reaction around the device. Mice that died during the course of the study; mice sacrificed in moribund condition, 10 mice of each sex at 3 and 15 months of the study, and remaining mice at the end of the 24-month study were euthanatized with CO₂ and necropsied. At necropsy, the skin at the implant site was shaved and a 2 × 3 cm section of skin with subcutaneous tissue and the device enblock was fixed in 10% neutral buffered formalin. The device was removed by carefully teasing the tissue capsule at one end so as to preserve the capsule and other tissue around the device as much as possible. The tissue without the device was embedded in paraffin and sectioned at 5 μm. The sections were stained with hematoxylin and eosin (H&E) and evaluated by light microscopy for tissue reaction around the device.

RESULTS

Two devices were lost and one failed within 10 days of implantation. One device, lodged in the subcutaneous tissue over the lumbar vertebrae, was pushed out slowly through the scar tissue of the injection site during the 10th month of the study. One device at each of the 58th, 75th and 104th week of the study failed. The failure of the devices, as determined by the manufacturer, was due to microscopic cracks in the weld of the antenna leads to the microchip in 3 devices and leakage of the glass capsule resulting in fluid accumulation around the microchip of one device.

Survival at the end of the 24-month study was 74% and 70% for the male and female mice, respectively. The mean body weights were 51.7 ± 9.8 (SD) g for male and 49.6 ± 6.3 g for female mice. The survival and average body weights of B6C3F1 mice in the diet control groups of 9 contemporary

¹ Registered Trade Mark of Bio Medic Data Systems, Inc., Maywood, New Jersey.

² Taconic Farms, Inc., Germantown, New York.

³ Type II See-Through System, Lab Products, Inc., Maywood, New Jersey.

⁴ Zeigler Bros., Inc., Gardners, Pennsylvania.

⁵ American Association for Accreditation of Laboratory Animal Care, Bethesda, Maryland.

⁶ Individual Sterile Needle Assembly, Trade Mark of Bio Medic Data Systems, Inc., Maywood, New Jersey.

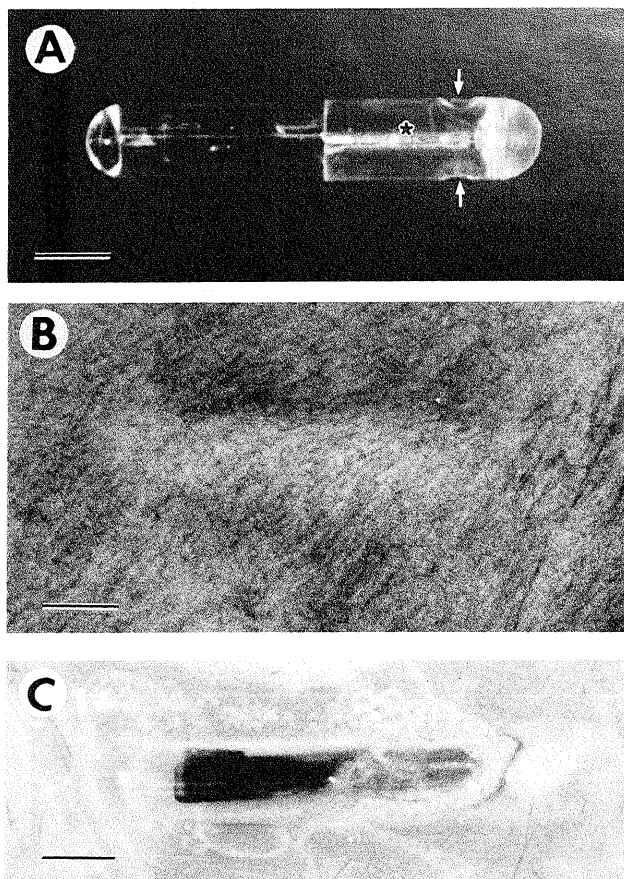


FIG. 1.—A. Glass sealed implantable micro-identification device (IMI) with polypropylene cap (*) and holes (arrows) in the polypropylene cap. B. Device in the subcutaneous tissue at 24 months—bulging of the skin was due to rigid glass sealed implant (IMI) and not due to tissue reaction. C. Appearance of the device in the subcutaneous tissue at the end of the 24-month study. Bar = 2 mm.

two-year studies sponsored by the NTP were $79.0 \pm 13.0\%$ survival with 48.6 ± 2.2 g body weights for the males and $70.7 \pm 11.3\%$ survival with 51.0 ± 5.0 g body weights for the females (NTP, unpublished data). The survival and average body weights of male and female B6C3F1 mice of this study were not significantly different from the diet control groups of the contemporary two-year studies done under similar animal care and management procedures.

All devices except 7 were palpable and appeared to be fixed at one location with no obvious inflammatory changes or palpable masses throughout the course of the 24-month study. Appearance of the subcutaneous implant is shown in Fig. 1B. The bulging of the skin was due to the rigid glass sealed device and not due to tissue reaction. Gross appearance of the device with the surrounding subcutaneous tissue at the end of the study is shown in Fig. 1C. Seven implants were not palpable during the course of the study but were detected by the transponder reader. At necropsy, these 7 devices were embedded in the

right perirenal tissue with no gross tissue reaction. The location of these devices appeared to be due to technical error during implantation resulting in implantation in the abdominal cavity rather than migration of these devices from the subcutaneous tissue. These devices were not palpable and the transponder reader could not identify the exact location of the device in these small animals, and so it was not known whether these devices migrated in the abdominal cavity and eventually fixed in the perirenal tissue or the initial implantation site was perirenal tissue.

Histologic examination indicated a capsule of variable thickness composed of fibrocytes and mature collagen fibers around most of the implants, especially the exposed glass surface of the device as shown in Figs. 2A and 2B. The capsule formed around the polypropylene cap of the device contained minimal to mild inflammatory reaction with lymphocytes, macrophages, and a few plasma cells and neutrophils. However, chronic granulomatous inflammation, as shown in Figs. 2C and 2D, was also observed around the polypropylene cap of 2 implants. Multinucleated foreign body giant cells were not observed in any of the sections examined. The capsule around the implant was more cellular at 3 and 15 months than at 24 months and the tissue reaction shown in Figs. 2C and 2D was from a female mouse necropsied at 15 months. The devices lodged in the abdominal cavity (perirenal tissue) did not show different tissue response. Neoplastic changes were not observed around the glass sealed devices with polypropylene cap for up to 24 months.

DISCUSSION

Neoplasms may emerge from areas of chronic fibrotic tissue reaction in response to injury due to asbestosis, schistosomiasis and foreign bodies (2). Carcinogenicity of implanted nondegradable materials in animals was reported by several investigators and results have been reviewed periodically (1-3). Mice, rats, and to some extent, dogs were found to be more susceptible to foreign body tumorigenesis than guinea pigs, chickens, and hamsters (2).

Experimental foreign body sarcomas of animals, like those in humans, appear in a variety of histological types including fibro-, fibromyxo-, heman-gio-, rhabdomyo-, reticulo-, osteogenic and other sarcomas. Materials of any type and chemical composition may cause tumors in animals if they possess smooth continuous surfaces and are nondegradable in the animal (2). The same materials in powder, perforated or porous form lose their tumorigenicity. Size and shape of implants determine the tumorigenic potential and there appears to be a linear correlation between surface area and tumor frequency (2). Different implant materials of equal size and

shape may still show marked differences in tumor incidence and latency due to differences in specific physico-chemical surface properties. The most important property appears to be smoothness of the surface and resistance to erosion. Tumor incidence markedly decreases and latency period increases when materials with rough surfaces are used (2).

The foreign body reaction of the mouse to a plastic disc in subcutaneous tissue includes mild granulomatous reaction (2) such as granulocytes and macrophages infiltrating the implant site, followed by development of thin coherent membrane around the implant consisting of fibroblasts and collagen fibers with sprouting of blood capillaries. During the following weeks, the membrane may thicken due to fibroblastic proliferation and collagen deposition, become relatively less cellular, and enter into a stage of quiescence by the third month (2). This can be microscopically discernible as a firm capsule around the implant. When plastics with rough surfaces are used, cellular reaction to the foreign body may be markedly protracted. Glass implants in comparison to smooth plastic implants of equal size may cause less vigorous foreign body reaction (2).

It was postulated (2) that a foreign body does not directly induce the carcinogenic process. However, it will stimulate cell proliferation, thereby increasing the chance of neoplastic transformation in the labile stem cells. By virtue of its presence, the nondegradable foreign body exhausts the macrophages and forces the reactive tissue into chronic fibrosis. In this state, there may be specific promotional effect on neoplastic transformation.

The glass sealed implantable micro-identification device (IMI) with polypropylene cap caused development of a thin coherent membrane consisting of fibrocytes and collagen fibers around the exposed glass surface with no indication of neoplastic changes to the end of the 24-month study. The reaction around the polypropylene cap of the device was more cellular with minimal to mild inflammation and occasional granulomatous reaction. The tissue reaction around the IMI was similar to that described by Brand (2). However, the IMI did not cause neoplastic changes at the site of implantation in the subcutaneous tissue or in the perirenal tissue, indicating that the glass used for sealing the device and polypropylene cap of the device are not carcinogenic in the mouse tissue for at least 24 months. Furthermore, these devices were highly reliable (>95%) and more dependable than other methods for the unique identification of mice in long-term studies.

ACKNOWLEDGMENTS

The authors acknowledge the collaboration of Bio Medic Data Systems and wish to thank the company

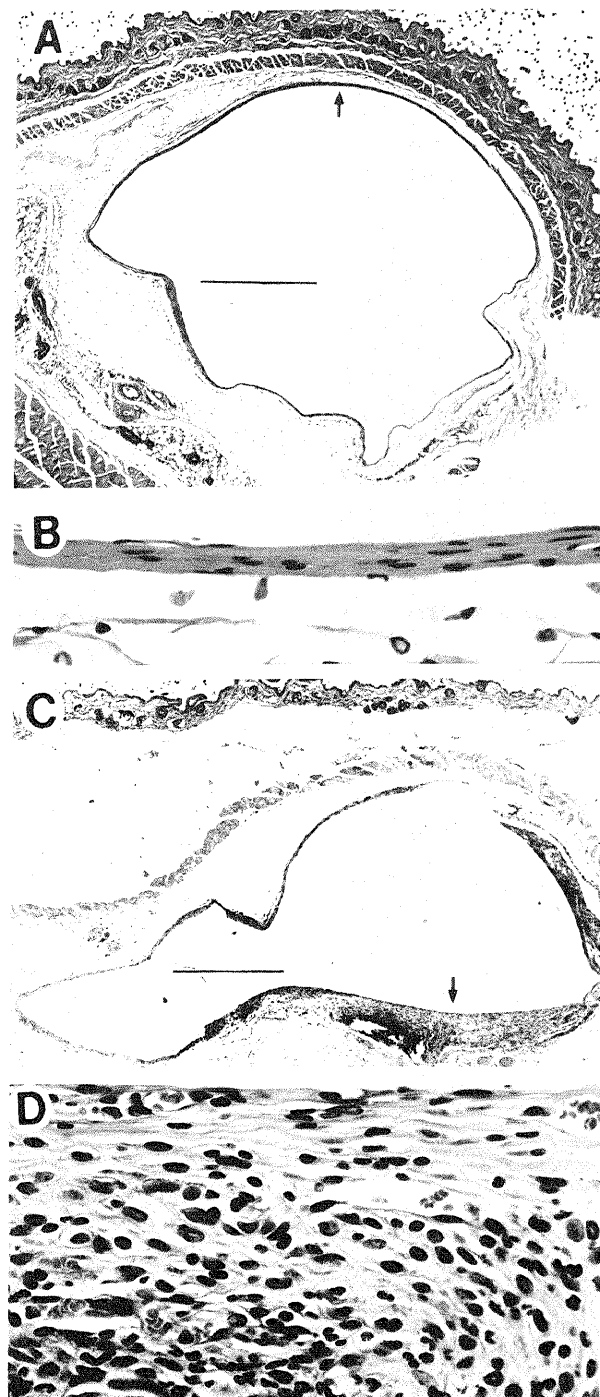


FIG. 2.—A. Tissue reaction with thin capsule (arrow) around the exposed glass surface of the device. Due to the thinness of the capsule, the round shape was not maintained when the device was removed. B. Magnification ($\times 10$) of the capsule of A at the area indicated by the arrow—thin capsule with fibrocytes and mature collagen fibers. C. Tissue reaction (arrow) around the polypropylene cap of the device. Since removal of the device resulted in tearing of some tissue that infiltrated into the holes of the polypropylene cap, the round shape of the capsule was not maintained. D. Magnification ($\times 10$) of the capsule of C at the area identified by the arrow—mild granulomatous reaction with macrophages and lymphocytes mixed with collagen fibers. Bar in Figs. A and C = 0.5 mm.

for supplying the implantable micro-identification devices and the low power radiofrequency signal probe reader. The authors also wish to thank Dr. Michael Elwell for reviewing the histological changes around the devices.

REFERENCES

1. Bischoff F and Bryson G (1964). Carcinogenesis through solid state surfaces. *Prog. Exp. Tumor Res.* 5: 85-133.
2. Brand KG (1982). Cancer associated with asbestosis, schistosomiasis, foreign bodies or scars. In: *Cancer—A Comprehensive Treatise. Etiology: Chemical and Physical Carcinogenesis*, FF Becker (ed). Plenum Press, New York, pp. 671-682.
3. Brand KG, Johnson KH, and Buoen LC (1976). Foreign body tumorigenesis. *CRC Crit. Rev. Toxicol.* 4: 353-394.
4. Food and Drug Administration (U.S. FDA) (1989). Good laboratory practice regulations. *Fed. Regis.* 54: 15923.
5. Haseman JK, Huff JE, Rao GN, Arnold JE, Boorman GA, and McConnell EE (1985). Neoplasms observed in untreated and corn oil gavage control groups of F344/N rats and (C57BL/6N × C3H/HeN)F1 (B6C3F1) mice. *J. Natl. Cancer Inst.* 75: 975-984.
6. Knapka JJ, Smith PK, and Judge FJ (1974). Effect of open and closed formula rations on the performance of three strains of laboratory mice. *Lab. Anim. Sci.* 24: 480-487.
7. National Research Council (1985). *Guide for the Care and Use of Laboratory Animals*. NIH publication 85-23. Washington, DC.
8. Waalkes MP, Rehm S, Kasprzak KS, and Issaq HJ (1987). Inflammatory, proliferative and neoplastic lesions at the site of metallic identification ear tags in Wistar [CrI:(WI)BR] rats. *Cancer Res.* 47: 2445-2450.